

# Targeted muscle reinnervation for symptomatic neuroma of deep peroneal nerve after below the knee amputation

Stephen J. Kovach, MD

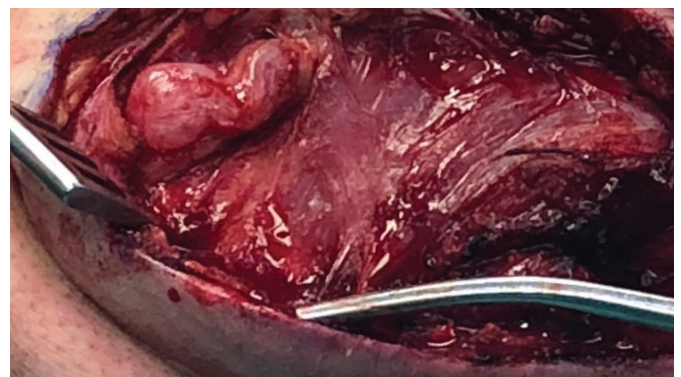
## Introduction

Residual limb pain after amputation can be debilitating for the patient. After amputation of the lower extremity, the occurrence of residual limb pain can range between 10 and 75%.<sup>1-4</sup> The formation of painful neuromas, in addition to chronic pain, can contribute to significant disability for the patient, such as the inability to ambulate in their prosthesis. The standard of care for treatment of neuroma in the past has been neurectomy followed by burying the transected end of the nerve in surrounding soft tissue or bone. This has universally resulted in poor outcomes and poor resolution of chronic pain.<sup>5-8</sup> Post amputation pain in this patient population secondary to neuroma formation is ubiquitous, and is a clinical problem commonly seen in amputee care.

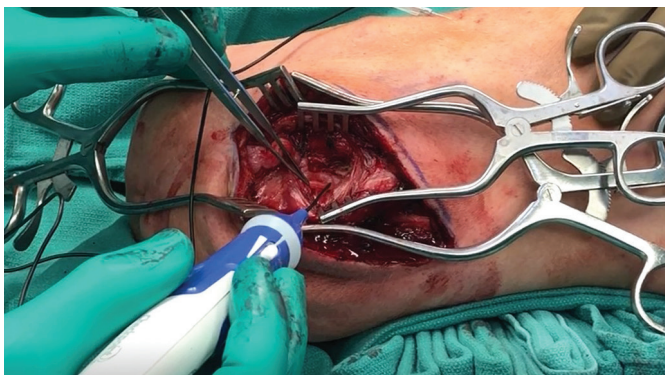Recently, targeted muscle reinnervation (TMR) has been shown to be an efficacious way to reduce post amputation pain both in the acute setting, from prevention of neuroma formation, as well as in delayed fashion after neuroma resection<sup>9-11</sup>. TMR is a welcome addition into the treatment algorithm of post amputation residual and phantom limb pain. The technique of TMR involves a nerve transfer, where the distal end of the transected nerve with neuroma involvement is coapted to a proximal motor branch target. This transfer of the painful nerve to a new motor target has been shown to both avoid subsequent neuroma formation, and reduce or eliminate postoperative neuroma pain. The identification of these proximal motor branches is facilitated by the use of the hand-held, biphasic nerve stimulator (Checkpoint Surgical, Inc. Cleveland, OH). I have found this device to be especially useful for mapping the location of these small, motor nerve targets either on the surface or just under the surface of muscle tissue, simplifying a rather tedious part of the procedure.

## Case

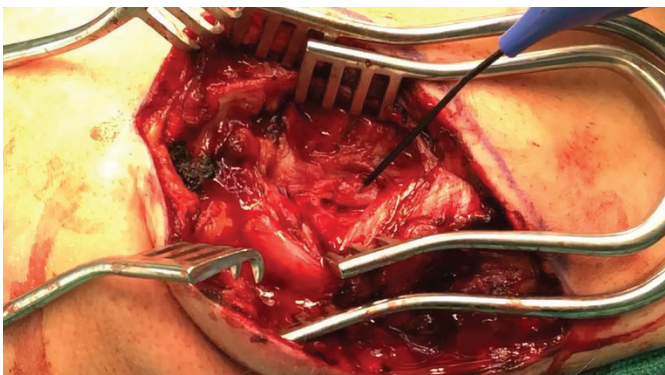
We present the case of a 38-year-old, left below the knee amputation with residual painful neuroma. The patient initially suffered a traumatic injury of his left lower extremity in an industrial accident. He initially underwent an attempt at salvage including microvascular free flap reconstruction of his extremity. He developed recurrent osteomyelitis and elected for a below the knee amputation. He was initially able to ambulate in a prosthesis, but developed debilitating pain in the distribution of his peroneal nerve, resulting in inability to wear his prosthesis and pursue his desired functional and recreational activities. Physical exam confirmed the presence of a palpable, exquisitely tender mass overlying his anterior compartment consistent with a neuroma of the deep branch of the peroneal nerve. He underwent a block of his common peroneal nerve with Marcaine<sup>TM</sup> with complete relief of his pain. Secondary to the complete pain relief with anesthetic blockade, he ultimately decided to pursue TMR for his symptomatic deep peroneal nerve neuroma.



**FIGURE 1. Dissection over the anterior compartment demonstrating large neuroma of the deep peroneal nerve.**



**FIGURE 2.** After dissection and definition of neuroma of deep peroneal nerve, the Checkpoint® nerve stimulator is used to map and identify the motor branches. Demonstrated is confirmation of proximal motor branches of the deep peroneal nerve with branches to extensor digitorum muscle body.



**FIGURE 3.** After resection of the neuroma, the proximal deep peroneal nerve is coapted to the motor branch to the extensor digitorum in an epineural fashion with 8-0 nylon with loupe magnification. Shown is the activation of the motor branch with the Checkpoint stimulator by stimulating the deep peroneal nerve proximal to the nerve coaptation demonstrating an intact nerve coaptation and conduction. This is possible due to the close proximity of the target muscle and stimulation through a coaptation to motor nerve recently transected.

## Conclusion

The patient was seen in follow up and is pain free after years of a symptomatic neuroma. He is now back in his prosthesis and has returned to his physical activity without pain.

**Stephen J. Kovach, MD**, is the Herndon B. Lehr, M.D. Endowed Associate Professor in Plastic Surgery at the Perelman School of Medicine at the University of Pennsylvania.



To view videos in article, scan QR code.

CS-9094-MKT-193-B

## References

1. Ephraim PL, et al. Phantom pain, residual limb pain, and back pain in amputees: results of a national survey. *Arch Phys Med Rehabil* 005;86:1910-1919.
2. Ehde DM, et al. Chronic phantom sensations, phantom pain, residual limb pain, and other regional pain after lower limb amputation. *Arch Phys Med Rehabil* 000;81:1039-1044.
3. Smith DG, et al. Phantom limb, residual limb, and back pain after lower extremity amputations. *Clin Orthop Relat Res* 1999;29-38.
4. Hsu E, et al. Postamputation pain: epidemiology, mechanisms, and treatment. *J Pain Res* 2013;121-136.
5. Jensen TS, Krebs B, Nielsen J, Rasmussen P. Phantom limb phantom pain and stump pain in amputees during the first 6 months following limb amputation. *Pain* 1983;17:243-256.
6. Jensen TS, Krebs B, Nielsen J, Rasmussen P. Immediate and long-term phantom limb pain in amputees: Incidence, clinical characteristics and relationship to pre-amputation limb pain. *Pain* 1985;21:267-278.
7. Pierce RO Jr, Kernek CB, Ambrose TA II. The plight of the traumatic amputee. *Orthopedics* 1993;16:793-797.
8. Ducic I, Mesbahi AN, Attinger CE, Graw K. The role of peripheral nerve surgery in the treatment of chronic pain associated with amputation stumps. *Plast Reconstr Surg* 2008;121:908-914; discussion 915-917.
9. JM, Cheesborough JE, Ko JH, Cho MS, Kuiken TA, Dumanian GA. Targeted muscle reinnervation: A novel approach to postamputation neuroma pain. *Clin Orthop Relat Res* 2014;472:2984-2990.
10. Valerio IL, Dumanian GA, Jordan SW, Mioton LM, Bowen JB, West JM, Porter K, Ko JH, Souza JM, Potter BK. Preemptive Treatment of Phantom and Residual Limb Pain with Targeted Muscle Reinnervation at the Time of Major Limb Amputation. *J Am Coll Surg* 2019 Mar;228(3):217-226.
11. Dumanian GA, Potter BK, Mioton LM, Ko JH, Cheesborough JE, Souza JM, Ertl WJ, Tintle SM, Nanos GP, Valerio IL, Kuiken TA, Apkarian AV, Porter K, Jordan SW. Targeted Muscle Reinnervation Treats Neuroma and Phantom Pain in Major Limb Amputees: A Randomized Clinical Trial. *Ann Surg* 2019 Aug;270(2):238-246.

The Checkpoint Stimulator is a single-use, sterile device intended to provide electrical stimulation of exposed motor nerves or muscle tissue to locate and identify nerves and to test nerve and muscle excitability. Do not use this Stimulator when paralyzing anesthetic agents are in effect, as an absent or inconsistent response to stimulation may result in inaccurate assessment of nerve and muscle function. For a complete list of warnings and precautions regarding the use of the Stimulator please see [www.checkpointsurgical.com](http://www.checkpointsurgical.com). Note: This Case Report is company funded and not peer-reviewed.

